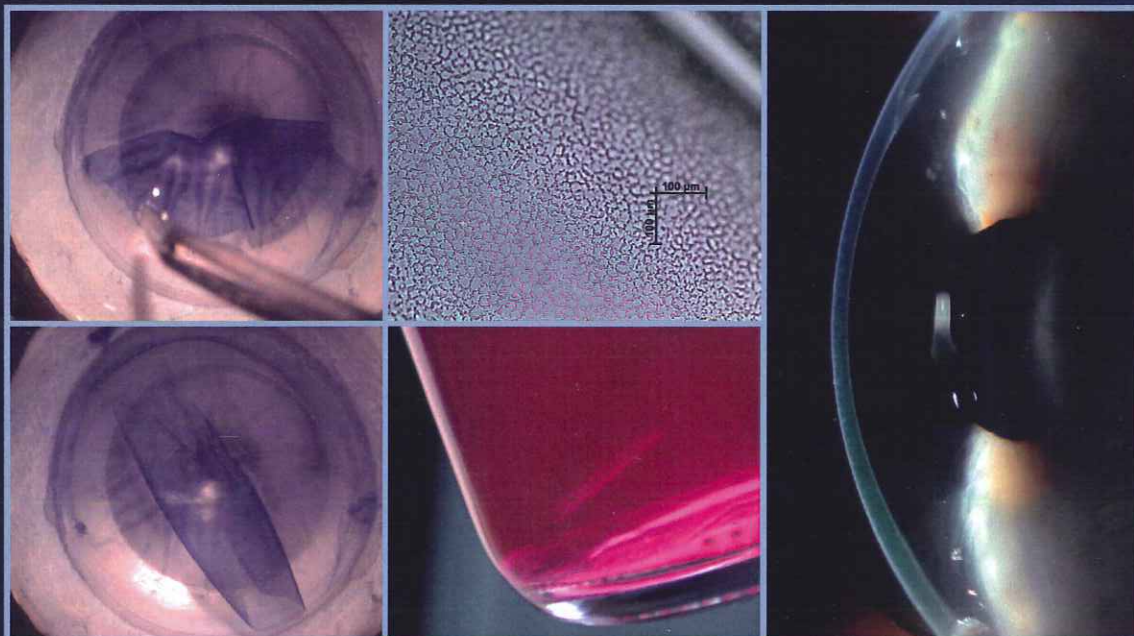


UNIVERSIDAD MIGUEL HERNÁNDEZ DE ELCHE
FACULTAD DE MEDICINA
DEPARTAMENTO DE PATOLOGÍA Y CIRUGÍA

DESCEMET MEMBRANE ENDOTHELIAL KERATOPLASTY (DMEK) DONOR TISSUE PREPARATION AND CLINICAL OUTCOMES



PhD THESIS

LISANNE HAM

Directores:

Gerrit R.J. Melles, MD, PhD, Director of the Netherlands Institute
for Innovative Ocular Surgery, Rotterdam, The Netherlands
Prof. Dr. D. Jorge L. Alió y Sanz, Catedrático de Oftalmología,
Universidad Miguel Hernández de Elche, Alicante

© L. Ham/ Nios, 2011

No part of this thesis may be reproduced or transmitted in any form
or by any means without permission of the author.

Layout and print by: Optima Grafische Communicatie Rotterdam

ISBN: 978-94-6169-180-4

UNIVERSIDAD MIGUEL HERNÁNDEZ DE ELCHE
FACULTAD DE MEDICINA
DEPARTAMENTO DE PATOLOGÍA Y CIRUGÍA

Gerrit R.J. Melles, MD, PhD, Director del Netherlands Institute for Innovative Ocular Surgery y el Prof. Dr. D. Jorge L. Alió y Sanz Catedrático de Oftalmología de la Facultad de Medicina de la Universidad Miguel Hernández de Elche

CERTIFICAN:

Que la tesis titulada "**Descemet membrane endothelial keratoplasty (DMEK): donor tissue preparation and clinical outcomes**" de la que es autora Dña. Lisanne Ham ha sido realizada bajo su dirección.

Y tras valorar el trabajo realizado por el aspirante al Título de Doctor,

AUTORIZAN:

Su presentación y defensa ante el Tribunal correspondiente.

Y para que conste a los efectos oportunos, firman el presente certificado en Alicante a 20 de Marzo del 2012.

Fdo: Dr. D. Gerrit R.J. Melles

Fdo: Prof. Dr. D. Jorge L. Alió

CONTENTS

1.	Aim and outline	13
2.	General introduction	17
2.1.	<i>History of corneal transplantation</i>	19
2.2.	<i>Macroscopic and microscopic functional corneal anatomy</i>	27
2.2.1.	Descemet membrane.	29
2.2.2.	The endothelium.	29
2.3.	<i>Posterior corneal diseases</i>	35
2.3.1.	Endothelial dystrophies: Fuchs endothelial dystrophy.	37
2.3.2.	Iridocorneal endothelial syndrome.	39
2.3.3.	Pseudophakic and aphakic bullous keratopathy.	40
2.4.	<i>Purpose, hypothesis and objectives</i>	45
2.5.	<i>Material and methods</i>	49
3.	Results	53
3.1.	<i>Endothelial keratoplasty</i>	55
3.1.1.	Endothelial keratoplasty: DSEK/DSAEK or DMEK-- the thinner the better? (Curr Opin Ophthalmol. 2009;20:299-307)	57
3.2.	<i>Donor tissue preparation</i>	69
3.2.1.	Donor tissue preparation for Descemet membrane endothelial keratoplasty. (J. Cataract Refract Surg. 2008;34:1578-1583)	71
3.2.2.	More efficient use of donor corneal tissue with DMEK: two lamellar keratoplasty procedures with one donor. (Br J Ophthalmol. 2010;94:1265-1266)	79
3.3.	<i>Clinical outcomes and visual rehabilitation</i>	83
3.3.1.	Visual rehabilitation rate after isolated Descemet membrane transplantation: DMEK. (Arch Ophthalmol. 2009;127:252-255)	85
3.3.2.	DMEK for Fuchs endothelial dystrophy: review of the first 50 consecutive cases. (Eye (Lond). 2009;23:1990-1998)	91
3.3.3.	Visus nach DMEK Ergebnisse der ersten 100 Eingriffe bei Fuchs'scher Endotheldystrophie. (Klin Monbl Augenheilkd. 2010;227:467-477)	103
3.3.4.	Secondary DMEK for poor visual outcome after DSEK: Donor posterior stroma may limit visual acuity in endothelial keratoplasty. (Cornea. 2010;29:1278-1283)	117

3.3.5.	Radial graft contraction may relate to subnormal visual acuity in DS(A)EK. (Br J Ophthalmol. 2010;94:951-953)	125
3.3.6.	Refractive change and stability after DMEK: Effect of corneal dehydration induced hyperopic shift on intraocular lens power calculation. (J Cataract Refract Surg. 2011;37: 1455-1464)	131
3.3.7.	Phacoemulsification after DMEK. (J Cataract Refract Surg. 2009;35:1314-1315)	143
3.4.	<i>Endothelial cell density</i>	147
3.4.1.	Endothelial cell density after DMEK: 1- to 2-year follow-up. (Am J Ophthalmol. 2009;148:521-527)	149
3.4.2.	Endothelial Cell Density after DMEK: 1- to 3-year follow-up. (Am J Ophthalmol. 2010;149:1016-1017)	159
3.4.3.	Endothelial cell density after DMEK: 1-4 year follow-up. (Am J Ophthalmol. 2011;151:1107-1107)	163
3.5.	<i>DMEK graft failure</i>	167
3.5.1.	Causes of primary donor failure in DMEK. (Am J Ophthalmol. 2008;145:639-644)	169
3.5.2.	Spontaneous corneal clearance despite graft detachment in DMEK. (Am J Ophthalmol. 2009;148:227-234)	177
3.5.3.	Persistent corneal edema after descemetorhexis without corneal graft implan- tation in a case of Fuchs endothelial dystrophy. (Cornea. 2011;30:248-249)	187
3.6.	<i>Clinical cases</i>	191
4.	Summary of results and general discussion	197
5.	Conclusions	207
6.	Curriculum vitae	211
7.	Other subject related publications by the author	215
8.	Congress presentations	219
9.	Acknowledgements	225